

Use of a novel needle wire in patients undergoing transseptal puncture associated with severe septal tenting

Marcus Wieczorek · Reinhard Hoeltgen · Elvan Akin ·
Ali Reza Salili

Received: 29 June 2009 / Accepted: 2 November 2009
© Springer Science + Business Media, LLC 2010

Abstract

Introduction An increasing number of patients undergo left atrial ablation procedures, since several approaches have proven efficacy in the treatment of atrial fibrillation. Although transseptal catheterization was generally shown to be a safe technique, it harbors the principal risk of cardiac injury. Therefore, there is a need for a safe and effective tool to enable transseptal puncture in difficult cases as well. **Methods and Results** In 158 consecutive patients, a transseptal puncture was intended for mapping and ablation of left atrial tachycardias. In seven patients of this series transseptal puncture using different sheaths and needle designs, the operators failed to cross the interatrial septum as a result of severe tenting. Three patients were known to have a septal aneurysm; a redo procedure was performed in two patients. In the remaining patients, there was no obvious explanation for the difficulty in crossing the interatrial septum conventionally. In all seven patients, a 120-cm-long nitinol guidewire (“needle wire”) with a 0.014-inch diameter was used to cross the atrial septum with the following idea: after tenting the fossa ovalis with the transseptal dilator and the Brockenbrough needle positioned just inside the tip, effortless advancement of the needle wire perforates the membranous fossa. Unsupported by the needle and dilator, the tip of the wire immediately assumes a “J” shape, rendering it incapable of further tissue penetration after its entry into the left atrium. In all seven patients, the needle wire could be placed into a left pulmonary vein. In five patients, a single attempt was sufficient to reach the left atrium with the wire, two

patients needed two and three attempts, respectively. No complications occurred.

Conclusions Additional use of a needle wire to perform transseptal puncture in a subset of patients at higher risk for complications appears safe and effective.

Keywords Transseptal puncture · Atrial fibrillation · Catheter ablation · Fossa ovalis · Septal tenting

1 Introduction

Transseptal puncture is a conventional approach to access the left atrium. Initially developed by Ross for measurement of left atrial pressure [1], this technique is now widely used in electrophysiological studies for performing catheter ablation procedures which target various arrhythmias such as left side accessory pathway tachycardias, ventricular tachycardias, left atrial tachycardias, and more recently, atrial fibrillation [2].

Despite growing popularity, catheterization of the left atrial chamber requires an experienced operator, and can be associated with potentially severe complications [3–6]. While generally a safe maneuver for most patients, the principal risk is cardiac perforation due to uncontrolled movement of the needle tip into the left atrium. This risk seems to be increased in patients with redo procedures as a result of fibrosis of the interatrial septum or in patients with a septal aneurysm [7, 8]. In both circumstances, excessive atrial tenting may result when applying conventional transseptal approaches. The aim of this study is to report first clinical results on efficacy and safety of a novel transseptal “needle wire” system for patients undergoing ineffective conventional transseptal puncture due to severe septal tenting.

M. Wieczorek (✉) · R. Hoeltgen · E. Akin · A. R. Salili
Department of Electrophysiology, Herzzentrum Duisburg,
Gerrickstrasse 21,
47137 Duisburg, Germany
e-mail: drmwieczorek@t-online.de

2 Methods

2.1 Patients

Seven patients with severe septal tenting in the course of a conventional transseptal puncture were enrolled into this study. They were part of a patient cohort with 158 consecutive patients undergoing a transseptal puncture for left-sided tachycardias. In all seven patients, the operators decided not to continue with a conventional transseptal puncture due to severe tenting of the left atrial septum. Clinical and echocardiographic data of the patients are presented in Table 1.

All patients underwent transesophageal echocardiography the day before transseptal puncture to exclude thrombus. Atrial septal aneurysm was defined as a protrusion of the aneurysm of >10 mm beyond the plane of the atrial septum.

2.2 Transseptal techniques

In all patients, conventional transseptal punctures (CTP) were performed with different transseptal needles (BRK XS, BRK-1 XS; St. Jude Medical, Minnetonka, MN, USA) and various transseptal-guiding introducers (Fast-Cath; St. Jude Medical, Minnetonka, MN, USA, Frontier Advance; AblationFrontiers, Inc., Carlsbad, CA, USA and Channel Steerable Sheath; Bard, Lowell, MA, USA) under fluoroscopic guidance in an 45° left anterior oblique view. A traditional approach was used to localize the fossa ovalis under fluoroscopic guidance. The sheath is placed in the right femoral vein and advanced into the superior vena cava over a guidewire. A pigtail catheter is positioned in the aortic root as anatomical landmark. Then, the guidewire is replaced with the Brockenbrough needle. All the components are flushed with saline prior to introduction. The transseptal assembly is then slowly withdrawn caudally,

keeping the needle hub arrow backward rotated between 3 and 5 o' clock until the tip engages the fossa ovalis. To ensure that the tip is against the fossa ovalis, small amounts of radio-opaque contrast are gently injected in order to visualize the interatrial septum. The needle tip can thus be seen tenting the fossa ovalis membrane with small movements of the entire transseptal apparatus. Finally, the septum is crossed with the needle only. Three to 5 cc of radio-opaque contrast are injected into the left atrium (LA) to again confirm positioning. With the transseptal needle stably positioned in the LA, the sheath and dilator are slowly advanced over the needle until the needle tip is well within the dilator. Once positioned, the dilator and transseptal needle are firmly stabilized as a unit, and the sheath is advanced further into the LA over the dilator. Prior staining of the fossa ovalis confirms that the sheath is well within the LA. If this technique did not allow crossing the fossa ovalis with the needle due to tenting of the interatrial septum, classified as either "moderate" or "severe," it was the operator's decision to subsequently attempt access to the LA with the needle wire system.

2.3 Needle wire system

The needle wire system is a 120-cm nitinol guidewire with 0.014-inch diameter (SafeSept™ Transseptal Guidewire, Pressure-Products Inc., San Pedro, CA, USA). It has a sharp and floppy "J-tip" that assumes a straight orientation while inside the Brockenbrough needle, allowing for crossing the septum, but will immediately prolapse upon entry into the LA. In practice, the system is introduced after the transseptal dilator has "tented" the fossa ovalis, with the Brockenbrough needle positioned just inside the dilator tip. Subsequently, a very small amount of pressure to the needle wire will advance through and perforate the membranous fossa. Unsupported by the needle and dilator, the tip of the wire immediately assumes a "J" shape, rendering it incapable of further tissue penetration (Fig. 1). A radiopaque coil on the shaft allows for visualization of the wire within the LA. The transseptal needle, dilator, and sheath are advanced "over the wire" into the LA after the needle wire is inserted within a left pulmonary vein which theoretically reduces the risk of aortic or pericardial perforation to nearly zero (Fig. 2).

3 Results

Transseptal puncture using the SafeSept needle wire system was successful in all seven patients with subsequent manipulation of the J-shaped wire into a left pulmonary vein. In five of the seven patients, the wire was manipulated into to left upper pulmonary vein, and in two cases, it was

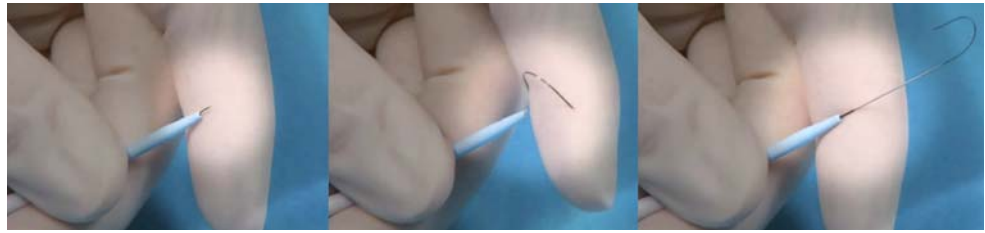
Table 1 Clinical and echocardiographic data

No. of patients (<i>n</i>)	158	7
Age (years)	56±6	54±7
Male (<i>n</i>)	112	2
LA size (mm)	42±4	43±4
AF procedure (<i>n</i>)	126	7
Redo procedure (<i>n</i>)	11	2
Septal aneurysm (<i>n</i>)	10	3
PFO (<i>n</i>)	38	0
LVEF (%)	58±5	61±4
Cardiac disease (<i>n</i>)	51	1

Mean ± standard deviation

LVEF left ventricular ejection fraction, LA left atrium, PFO patent foramen ovale

Fig. 1 The needle wire is leaving the sheath. Unsupported by the needle and dilator, the tip of the wire immediately assumes a “J” shape. See text for further details



placed in the left inferior pulmonary vein, following a natural course after puncture. In five patients, a single attempt was sufficient to reach the LA with the wire, two patients needed two and three attempts, respectively, with both patients were known to have a septal aneurysm.

Two of the seven patients with severe septal tenting were undergoing a redo procedure for paroxysmal atrial fibrillation, three patients were diagnosed as having a septal aneurysm prior to the investigation, and two patients had no apparent explanation for septal tenting. In all cases, the desired sheath could be manipulated over the wire into the LA without complications, irrespective of selection to the left-sided pulmonary veins. The wire proved stiff enough to allow the dilator and sheath to cross the atrial septum in all cases. Tenting of the interatrial septum appeared to be less extensive, when puncture was performed with the needle wire compared with the Brockenbrough needle (Table 2). The degree of tenting was considered to be “moderate” in the estimation of

the operators in three patients by using the needle wire, which was formerly classified as “severe” with the conventional puncture technique.

Mean fluoroscopy time from tenting the atrial septum with the sheath to final placement of the sheath into the left atrial body over the needle wire was 135 ± 48 s (65–311 s).

4 Discussion

The need for transseptal puncture to gain access to the LA is increasing with the rise in left atrial electrophysiology procedures, closure of left atrial appendage, and other procedures. Transseptal puncture carries a low, albeit real, risk of cardiac perforation to the posterior LA or anteriorly to the ascending aorta [4]. Possible complications associated with the transseptal puncture can occur in approximately 1% of procedures. In one

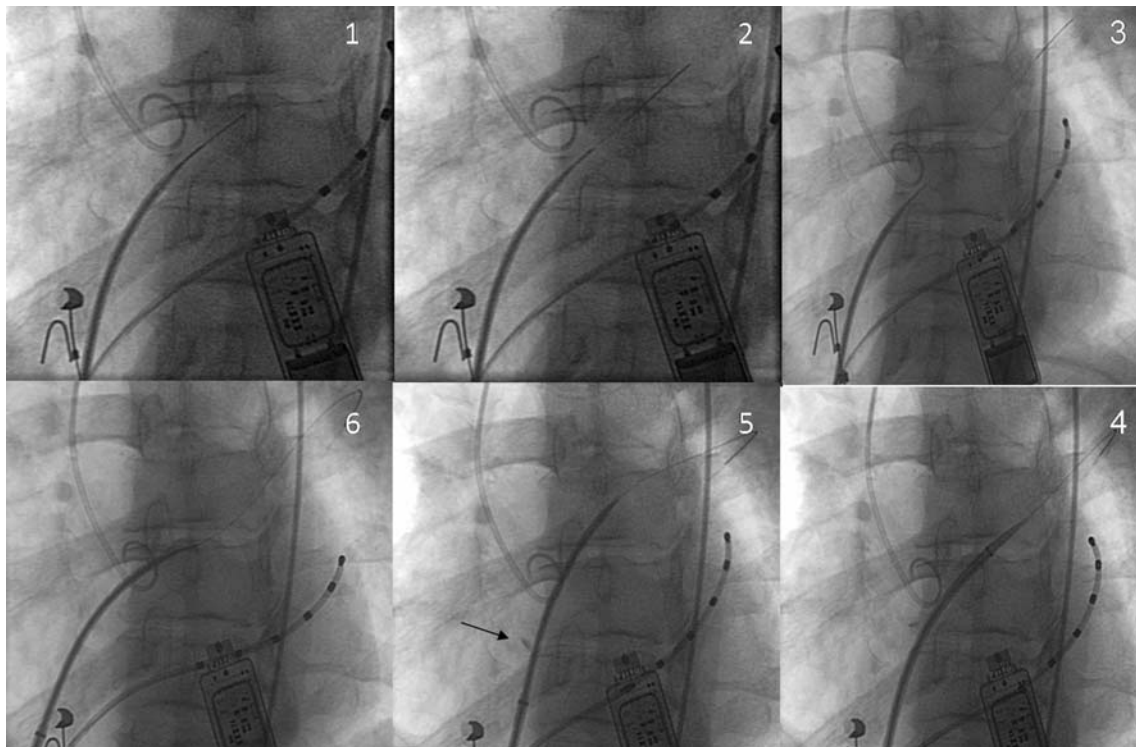


Fig. 2 Step-by-step transseptal puncture using a needle wire (1–6). See text for detailed explanation of each step. Small deposit of contrast medium within the interatrial septum (arrow). A pigtail catheter is placed near the aortic roof, a multipolar catheter is in the coronary sinus

Table 2 Qualitative degree of tenting

Patient	Diagnosis	Tenting CTP	Tenting SafeSept
1	SA	Severe	Moderate
2	Redo	Severe	Severe
3	Unknown	Severe	Severe
4	SA	Severe	Moderate
5	SA	Severe	Severe
6	Redo	Severe	Moderate
7	Unknown	Severe	Severe

single-center review of 1,150 patients undergoing transseptal puncture for atrial fibrillation (AF) ablation, no failures or serious complications attributable to the puncture were reported [5]. In a larger multicenter review of 5,520 patients, 0.9% of procedures were abandoned because of inability to locate the fossa ovalis, tough atrial septum, perforation of the aortic root, or most commonly perforation of the RA into the pericardial space [4]. Stretching and/or increased force to traverse the septum is required with elastic, aneurysmal, or thickened interatrial tissue in some patients [7]. In rare cases, stretching of the interatrial septum closely approaches the lateral left atrial wall, increasing the risk for perforation.

During a standard transseptal puncture, the needle is advanced through the dilator tip to puncture the septum. The septum may be easily stretched, aneurysmal, or thickened with fibrotic tissue. Thus, frequently, the entire needle/dilator–sheath assembly would need to be advanced further, building pressure of the needle tip on the septum, in order to puncture it. Severe tenting of the interatrial septum will occur in this situation. When such additional force is applied to the assembly, the needle, and sometimes, the entire dilator–sheath assembly, lurches forward at the moment of puncture, increasing the risk of left atrial posterior wall perforation. We performed successful transseptal puncture in seven out of 158 patients with a needle wire where conventional puncture with a Brockenbrough needle resulted in severe atrial tenting without any complications. This led to a series of 158 consecutive patients, in which no puncture-associated complications were seen at all.

Two aspects of the needle wire seem to decrease the potential complication rate in transseptal puncture: The sharpness of the needle reduces the stretching forces necessary to penetrate the septum, reducing the extent of septal tenting in some patients. More importantly, the prolapse of the needle tip into a “J” shape after transversing the septum renders it almost incapable of further tissue penetration. The atraumatic distal “J” shape of the needle

wire and the stiffness of the wire in combination with its distal position in one of the left-sided pulmonary veins enables the operator to firmly cross the atrial septum with the dilator and the sheath sequentially, if necessary (e.g., thickened and/or fibrotic atrial septum), since the needle wire itself does not reduce the forces necessary to cross the septum in such cases.

In the literature, there is one other technique which is able to reduce the stretching forces applied to the septum during the puncture: some groups described a technique that facilitates transseptal puncture by applying brief pulses of radiofrequency energy from a standard electro-surgical cautery generator through the needle tip, thus penetrating the septum [9–11], while others use a specifically designed catheter for radiofrequency transseptal puncture (Toronto Transseptal Catheter, Baylis Medical Company, Inc, Montreal, Canada) [10, 11]. Most groups limit this technique to patients where a conventional puncture of the septum is difficult or unsuccessful, as it was in our series of patients [9]. Some others advocate the use of a 0.014-inch wire as soon as the needle tip has entered the LA [12]. This is generally done in order to minimize the risk of perforation from additional movements of the transseptal needle and further confirm the correct positioning of the transseptal needle within the body of the LA, but does not eliminate the risk of uncontrolled needle movement after it penetrates a stretched atrial septum. Many experienced centers advocate the use of intracardiac echo (ICE) for guidance of complicated transseptal puncture [13]. This might further enhance the safety using the needle wire, since erroneous advancement of the wire into the left atrial appendage instead of the left pulmonary veins could be clearly detected and cardiac perforation thus be avoided.

ICE offers some additional advantages in performing left atrial procedures: it can be used for selective puncture of the fossa according to the needs, e.g., more anterior puncture for accessory pathway ablation and more posterior/inferior for ablation procedures targeting the pulmonary veins. It can be used throughout the entire procedure to maximize safety.

ICE has a critical role for assisting placement of mapping and ablation catheters, and allows for titration of energy delivery. More importantly, it allows identification and potential reduction of procedural complications including damage to intracardiac structures, left atrial thrombus formation, pulmonary veins stenosis, and pericardial effusion during left heart ablation [14].

There are potential complications when using the specific needle wire system for transseptal puncture: entrapment of the J-tip into the mitral valve apparatus, after the wire dislodges from the pulmonary veins by advancing the sheath into the LA. Although perforation

of a sheath previously placed transseptally using the needle wire system is an unlikely scenario due to its special design, this situation cannot be completely ruled out and underlines the need for careful monitoring by fluoroscopy when performing procedures with multiple transseptal catheters.

5 Conclusions

Additional use of a needle wire to perform transseptal puncture in a subset of patients at higher risk for complications appears safe and effective. While the number of left atrial ablation procedures increases, resulting redo procedures may create a subset of patients with a higher risk profile that can be successfully managed with this technique.

References

- Ross, J., Jr., Braunwald, E., & Morrow, A. G. (1959). Transseptal left atrial puncture; new technique for the measurement of left atrial pressure in man. *American Journal of Cardiology*, *3*, 653–655.
- Haissaguerre, M., Shah, D. C., Jais, P., Hocini, M., Yamane, T., Deisenhofer, I., et al. (2000). Electrophysiological breakthroughs from the left atrium to the pulmonary veins. *Circulation*, *102*, 2463–2465.
- Cappato, R., Calkins, H., Chen, S. A., Davies, W., Iesaka, Y., Kalman, J., et al. (2005). Worldwide survey on the methods, efficacy, and safety of catheter ablation for human atrial fibrillation. *Circulation*, *111*, 1100–1105.
- De Ponti, R., Cappato, R., Curmis, A., Della, B. P., Padeletti, L., Raviele, A., et al. (2006). Trans-septal catheterization in the electrophysiology laboratory: data from a multicenter survey spanning 12 years. *Journal of the American College of Cardiology*, *47*, 1037–1042.
- Fagundes, R. L., Mantica, M., De Luca, L., Forleo, G., Pappalardo, A., Avella, A., et al. (2007). Safety of single transseptal puncture for ablation of atrial fibrillation: retrospective study from a large cohort of patients. *Journal of Cardiovascular Electrophysiology*, *18*, 1277–1281.
- Marcus, G. M., Ren, X., Tseng, Z. H., Badhwar, N., Lee, B. K., Lee, R. J., et al. (2007). Repeat transseptal catheterization after ablation for atrial fibrillation. *Journal of Cardiovascular Electrophysiology*, *18*, 55–59.
- Tomlinson, D. R., Sabharwal, N., Bashir, Y., & Betts, T. R. (2008). Interatrial septum thickness and difficulty with transseptal puncture during redo catheter ablation of atrial fibrillation. *Pacing and Clinical Electrophysiology*, *31*, 1606–1611.
- Hu, Y. F., Tai, C. T., Lin, Y. J., Chang, S. L., Lo, L. W., Wongcharoen, W., et al. (2008). The change in the fluoroscopy-guided transseptal puncture site and difficult punctures in catheter ablation of recurrent atrial fibrillation. *Europace*, *10*, 276–279.
- Bidart, C., Vaseghi, M., Cesario, D. A., Mahajan, A., Fujimura, O., Boyle, N. G., et al. (2007). Radiofrequency current delivery via transseptal needle to facilitate septal puncture. *Heart Rhythm*, *4*, 1573–1576.
- Casella, M., Dello, R. A., Pelargonio, G., Martino, A., De Paulis, S., Zecchi, P., et al. (2008). Fossa ovalis radiofrequency perforation in a difficult case of conventional transseptal puncture for atrial fibrillation ablation. *Journal of Interventional Cardiac Electrophysiology*, *21*, 249–253.
- Sakata, Y., & Feldman, T. (2005). Transcatheter creation of atrial septal perforation using a radiofrequency transseptal system: novel approach as an alternative to transseptal needle puncture. *Catheter Cardiovasc Interv*, *64*, 327–332.
- Hildick-Smith, D., McCready, J., & de Giovanni, J. (2007). Transseptal puncture: use of an angioplasty guidewire for enhanced safety. *Catheterization and Cardiovascular Interventions*, *69*, 519–521.
- Hanaoka, T., Suyama, K., Taguchi, A., Shimizu, W., Kurita, T., Aihara, N., et al. (2003). Shifting of puncture site in the fossa ovalis during radiofrequency catheter ablation: intracardiac echocardiography-guided transseptal left heart catheterization. *Japanese Heart Journal*, *44*, 673–680.
- Saliba, W., & Thomas, J. (2008). Intracardiac echocardiography during catheter ablation of atrial fibrillation. *Europace*, *10*(Suppl 3), iii42–iii47.